

ISSN 0704-3716

Canadian Translation of Fisheries and Aquatic Sciences

No. 5633

Infestation with lung worms in seals (*Phoca vitulina* L.)
under natural conditions

E. Menschel, B. Schiefer (Institute of Zoopathology)
H. Kraft (Medical Veterinary Hospital)
Munich, Federal Republic of Germany

In: Berliner und Münchener Tierärztliche Wochenschrift
v. 17 : pp. 333-337, 1966

Original language: German

Available from:
Canada Institute for Scientific and Technical Information
National Research Council
Ottawa, Ontario, Canada K1A 0S2

20 typescript pages

Infestation with lung worms in seals (*Phoca vitulina* L.)
under natural conditions

by E. MENSCHEL, H. KRAFT and B. SCHIEFER

With 11 illustrations[†]

The only hunted sea mammal to be found in our latitudes is the European seal (*Phoca vitulina* L.). Although protected to a certain extent - new shooting quotas are set following annual counts - seals do not multiply extensively. Herds can be found at low tide on sand-banks off the North Sea coast. The experienced and healthy adult seal is very cautious and not approachable. By comparison, the weak juveniles and the diseased seals show their shyness at a later stage and are thus an easy prey. However, diseased seals are very aggressive and also snappish, even though their movements on land are very ungainly.

Older seals are frequently infested with endoparasites, especially in the lungs. As the live animal shows only few symptoms of

those diseases, heavy breathing is in most cases the only possible sign of verminous pneumonia (РЕЙНЕК, 1958). If a faecal sample can be collected from the animal concerned on land - seals usually deposit their faeces in the water - it is important that the tests on the faecal sample include the migration technique in order to confirm the presence of lungworm larvae.

Filarial infestation in the heart of a live seal can only be detected through a blood test. The presence of microfilariae in the "thick drop" confirm the suspicion of filariasis. An eosinophilia in peripheral blood is indicative of a lungworm infestation. Taking blood samples from a seal is not too difficult once the animal is securely held. The skin is so hypervascular

[†]Translator's note:
this document.

The translation of each caption can be found on pages 10 to 20 of

that enough blood can be collected for the "thick drop" or a smear by simply the skin. A puncture of one of the veins on the volar side of the fore flipper will provide as much blood as desired (subject of course to the total volume of blood available). The blood morphology of the European seal is known (KRAFT, 1966).

Nematodes of the species *Otastrangylus circumlitus* are a common occurrence in harbour seals (*Phoca vitulina*) and ringed seals (*Phoca hispida*) (RAILLIET, 1899) BRUYH 1933, (RAILLIET, 1899; SKRJABIN, 1933; SKRJABIN et al., 1954; DE BRUYH, 1933; MOHR, 1952 ; WOLINSKI and LANDOWSKI, 1962; VAN HAAFTEN, 1962). The parasites may be found not only in the aeriferous tissues of the lungs but also in the arteries (pulmonary artery), in the right ventricle and in the hepatic blood vessels. The present authors' position in this regard is described below.

In addition, the following species of filariae are also found in the right ventricle and in the pulmonary arteries of seals: *Dipetalonema*- (syn.: *Skrjabinaria*) (e.g. *Dipetalonema spirocauda* LEIDY,

1958; cf. BROWN et al., 1960; KREIS, 1953; VAN DEN BROEK and WENSVOORT, 1959; TAYLOR et al., 1961) and *Parafilaroides* (syn.: *Pseudalius*, *Halocercus*, *Filaroides*) *gymnurus* DOUGHERTY, 1946 (cf. VAN DEN BROEK and WENSVOORT, 1959; VAN HAAFTEN, 1962).

Our own examinations

Patho-anatomical and histological findings

Starting in 1961, 18 seals of various age levels were examined. 12 of these animals were between the age of 3 days and 3 weeks (so-called "wailing pups"). The following causes of death were found: omphalophlebitis (1x), purulent meningo-encephalitis (2x), aspiration of food into the lungs (4x), various bacteraemia (3x). No specific cause of death could be established for two animals. The lungs of the 12 seals were found to be free of parasites, while verminous pneumonia was diagnosed for three seals between the ages of 6 and 12 months. Two animals were found to have both verminous pneumonia and a filarial infestation of the blood vessels (in particular the right ventricle and the pulmonary artery). In one case filariae could only be found in the heart; it was

not possible, however, to establish the presence of microfilariae in the blood.

In addition to verminous pneumonia, one of the seals, a six month old female, displayed ventral excoriation of the skin, about as large as a human hand, in the umbilical region (Fig. 1). As shown by the histological examination (Fig. 2), there was a necrosis of the upper skin layers and the subcutaneous connective tissues. There were plenty of granulocytes underneath the peripherally lifting callous layer as well as in deeper tissue layers, while around the middle of the ulcer the decomposition and the poor stainability of the tissue increased and showed a multibacterial flora. On the basis of a bacteriological examination, β -haemolytic streptococci were identified.

The lung, pale pink in colour, shows compacted areas attributable to an infestation with *Otostrongylus circumlitus*. Areas of alveolar and interstitial emphysema alternate with one another. In the bronchi there are masses of the 10-14 cm long, whitish looking roundworms; these take up the whole bronchial lumen and

also cause the partial formation of emphysema and atelectasis (Fig. 3).

A careful examination will allow the expert to find somewhat smaller (4-7 cm long) darker looking nematodes in the pulmonary vessels.

Histological tests show that fully developed female parasites are to be found in the alveolar space or in the bronchioles and the bronchi (Fig. 4 and 5). The parasites seen in cross section display all the developmental stages of ovogenesis (Fig. 5). However, it was not possible through histological tests to detect parasites, in particular fully developed worms, in the vessels (Fig. 6). The atelectatic tissue areas are clear-cut and alternate with areas of an alveolar emphysema. It is worth noting that the tissue reaction to adult parasites is rather scanty and is limited to a slight proliferation of lymphohistiocytic cell elements. The massive appearance of larvae in the bronchi generates, however, a strong neutrophil leucocytic reaction.

Parasitological examination

5 of the 6 seals infested with parasites were subjected to thorough parasitological testing. It turned out that in three cases the parasites involved were fully developed nematodes of the genus *Otostrongylus* (family: *Dictyocaulidae*, according to the nomenclature of SKRJABIN et al., 1952). We identified the nematodes as *Otostrongylus circumlitus* (RAILLIET, 1899), BRUYH, 1933 (syn.: *Strongylus circumlitus* RAILLIET, 1899, *Kutastrongylus andreewoi* SKRJABIN, 1933, *Kutasicaulus andreewoi* SKRJABIN, 1933).

A filarial infestation was present simultaneously in two cases, and in one of those cases the filariae were found in the heart only. They were identified as *Dipetalonema spirocauda*.

The following description of findings is limited to parasites of the genus *Otostrongylus*. Males isolated in the bronchi (Fig. 3) were 9-11.5 cm long and 1.3 mm thick at the most; females were between 11 and 14 cm long and 2.4 mm thick at the most. Males isolated in the pulmonary artery were 4.5-6.5 cm long and 0.75 cm thick at the most, while

females were 4-7.5 cm long and 0.75 cm thick at the most. *Otostrongylus circumlitus* has cephalad at times highly developed horizontally striped cuticular processes extending up to the level of the excretory pore (Fig. 7). The mouth has no lips and is surrounded by 12 smaller papillae (outer circle) standing in pairs next to a larger papilla (a total of 6, inner circle). Each of these 18 papillae carries a bristle. The small funnel-shaped mouth capsule is slightly chitinized, its inner wall is fitted with a concentric row of very small denticles. The oesophagus of the examined specimens was 980 μ long and 150 μ wide on average (aside from a slight constriction in the area of the nerve ring). The midgut, which follows, shows two swellings in its first section.

When extended, the *Bursa copulatrix* of the males (Fig. 8) is almost circular, shell-shaped, not subdivided into flaps. It is supported by 9 well-developed ribs: 2 ventral, 2 antero-lateral, 2 lateral, 2 externo-dorsal, and 1 dorsal. The ventral rib divides in the middle of its length in 2 branches running close and parallel to one another. It is considerably distant from the other ribs. The

antero-lateral and lateral ribs share a wide and very short trunk. The distal end of the antero-lateral rib is club-shaped and thickened. Like the ventral, the lateral rib branches in the middle of its length. The externo-dorsal rib rises isolated and, like the antero-lateral rib, shows a club-shaped thickening of its distal end. The dorsal rib emerges from two ribs with two separate origins. These two ribs come gradually closer to one another in their further course and merge into their distal end in the median. Two lateral prominences give the common end the appearance of a two-pronged fork. DE BRUYN (1933) draws the genus name *Oto-strongylus* from these ear-shaped prominences, both pointing ventrad. The spicules (Fig. 9) of the examined males were between 490 and 630 μ long and 75 μ at the most. The body of the spicule is dark brown and has a spongy structure. A hyaline wing can be seen on its ventral, and one on its dorsal surface. The dorsal wing produces a narrow protuberance in the last third of its length. This protuberance is surrounded by a transparent membrane which merges into the body of the spicule. The distal end of the spicule is finger-shaped and somewhat bent inward. There is a gubernaculum

which, like the spicule, is covered with verruciform prominences.

The vulva of the female is located near the middle of the body. Eggs and larvae at all stages of development can be found in the uterus. The posterior end of the female is pointed like a cone, bent ventrad, and ends with a small, trident papilla that can only be recognized in side view (Fig. 10). Beginning in front of the anus, the cuticle of the posterior end is more or less strongly distended - in the hindmost area irregularly. This distension of the cuticle has a thin transverse striation and shows a sinusoidal retraction around the anus.

First-stage larvae of *Otostrongylus circumlitus* (Fig. 11), masses of which were traced in the rectal contents of a dead seal, measured between 350 and 490 μ in length and 21 μ in thickness at the most. The anterior end of the larvae had the shape of a truncated cone. Given its eccentric location, the mouth can, when seen in a lateral position, look like a kind of umbonal thickening. The cuticle runs from the anus to the tip of the tail.

The upwardly bent posterior end tapers to a point.

Discussion

The literature on the subject keeps on pointing to the presence of *Otostrongylus circumlitus* not only in the aeriferous tissues of the lung, but also in the arteries (pulmonary artery), in the right ventricle and in the hepatic blood vessels. According to our own observations, it is reasonable to assume that the parasites found in the blood vessels are juvenile stages. We could find females with larvae inside only in the alveoli and the bronchi.

Among the authors referred to in the literature, only RAILLIET gives a more precise description of the larvae, with the exception of a description with illustration by LJUBIMOV (1927). The latter refers, however, to the larvae found in the small intestine of a seal (*Phoca vitulina*) as the early stages of a type of filariae, *Skrjabinaria spirocauda*, of which he gave a new description. These larvae looked in fact like the larvae from the only female he had isolated in fragments together with the complete specimen

of a male found in the heart of the same seal. Both the larvae from the small intestine and the "filarial" female probably represented *Otostrongylus*. As for the male, it was undoubtedly a filaria taxonomically listed by ANDERSON (1959) as a member of the genus *Dipetalonema*.

The importance of the differentiation and the exact parasitological determination of nematodes is underlined by the fact that there may also be filariae in the blood vessels of the lungs.

Histological findings from a filarial infestation differ considerably from the alterations caused by *Otostrongylus circumlitus*. In the case of filariae, vascular alterations are prominent: in addition to the proliferation of subintimal connective tissues, there is also, more often than not, a thrombosis of the arteries with subsequent infarction in the lung parenchyma, followed by scarring (TAYLOR et al., 1961). However, such tissue alterations have not been observed in cases of infestation with *Otostrongylus*. Finally, one must bear in mind that it should be possible to identify microfilariae in

the blood in cases of infestation with *Otostrongylus*. Further investigations in this direction appear to be indispensable.

Like *Otostrongylus*, *Parafilaroides gymnurus* infests the bronchi and the alveoli and the symptoms it engenders are more like those of a catarrhal purulent bronchopneumonia. The findings for the lung thus resemble - with the exception of the size of the parasites which can be up to 2 cm in length - those from an infestation with *Otostrongylus* so that it is also possible to differentiate here.

As already established by VAN DEN BROEK and WENSVOORT (1959), very little is known about the life cycle of the lungworms found in seals. It has not been ascertained to date whether the larvae - after passing through the intestine - need a secondary host or are swallowed again by seals after a certain period of time spent in the water in which they can survive for a long time (DE BRUYN, 1933).

Critical observations must also be made with regard to the skin lesion we observed in one case. As a matter of fact, VAN HAAFTEN (1962)

found multiple abscesses in the skin of European seals, for the most part ventrad in the umbilical region and around the mouth, but he did not attempt to define their etiology. One could most likely attribute a purely traumatic origin to these ventral skin alterations. This interpretation is, however, contradicted by the fact that seals prop themselves up on either the inframammary area or even further caudad, on the abdomen in the pelvic area, a process which causes the hairs in that area to wear off. Therefore, we would like to interpret the skin alterations found in the umbilical region as the clinical picture known by the name of *Ecthyma streptogenes* (GANS and STEIGLEDER, 1955) in human beings. A degradation of the nutritional state or serious illnesses of a general nature probably favour the appearance of *Streptoderma epidermido-cutanea circumscripta ecthymatosa*.

Finally, with regard to therapeutic measures applied to European seals infested with lungworms, we should mention that the aerosol therapy with parasiticides has already been applied successfully to captive seals (REINECK, 1958) and that there are plans to try

prophylactic injections at some point in the future. On the other hand, we think that the lungworm infestation in seals living under natural conditions is impossible to control. It also appears that the treatment of the filarial infestation is not very promising, except by surgical means as has already been done for dogs.

• For seals held in captivity, it should still be possible to detect parasitic diseases in time by testing blood and faecal samples and to apply the proper treatment.

Bibliography

(translation of titles limited to languages other than English or French)

- (1) Contributions to the study of *Strongylus circumlitus* Railliet in the lungs of the seal: the new genus *Otostrongylus*.
- (2) Histology of skin diseases
- (3) Blood morphology of the European seal
- (4) Contributions to the study of parasitic nematodes XIII *Skrjabinaria heteromorpha* n. sp. (*Filariodea* Weinland 1858; Stiles 1907) of the seal (*Phoca vitulina* L.)
- (5) Contribution to the study of the helminthic fauna in animals of the Moscow Zoo
- (6) Seals in European waters
- (7) Young seals: A breeding problem
- (8) Basic principles of nematodology
- (9) On cases of disease and death in the seal population of Polish zoos

Authors' address:

Dr. Elkemarie Menschel, Priv.-Doz. Dr. B. Schiefer (docent)
Institut für Tierpathologie

Prof. Dr. H. Kraft
Medizinische Tierklinik
Veterinärstrasse 13

- 8000 München 22 [Federal Republic of Germany]

*Translation of the captions
(Figures 1 to 11)*




Fig. 1 Skin ulcer on a six month old female seal (A 157/65)




Fig. 2 Necrosis of the deeper tissue layers in the area of the ulcer (*Ecthyma streptogenes*); HE, magnifier



Fig. 3 Fully developed females of *Otostrongylus circumlitus* in the bronchi (a) and juvenile stages in the pulmonary artery (b) (A 157/65)



Fig. 4 Verminous pneumonia: fully developed females of *Otostrongylus circumlitus* in the bronchi. Pulmonary emphysema and localised pneumonia (A 157/65); HE, magnifier



Fig. 5 *Otostrongylus circumlitus* (with larvae at various stages of development on the inner side) in the bronchioles and in the alveoli (A 157/65); HE. magnifier

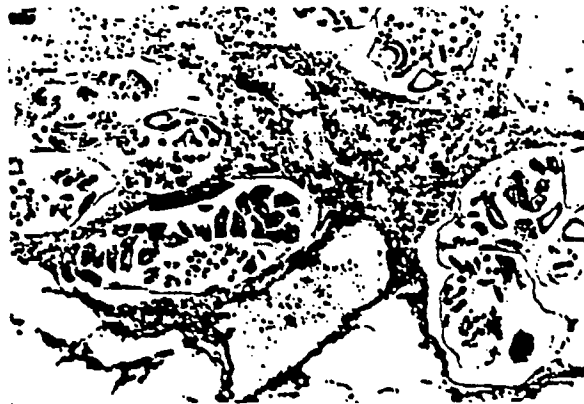

Fig. 6 Various cut surfaces of parasites in aeriferous tissues. Noteworthy is the absence of nematodes in the vessels. No inflammatory vascular alteration is to be seen (A 157/65); HE, 70x




Fig. 7 *Otostromgylus circumlitus*. Anterior end. Magnification 85x
(Photographic Archives, Zooparasitological Institute)

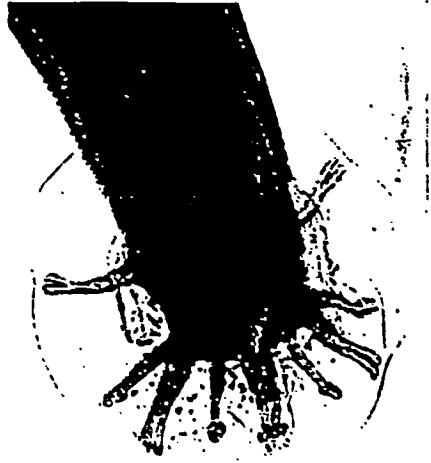


Fig. 8 *Otostrongylus circumlitos*. Posterior end of a male. Original. Magnification 70x (Photographic Archives, Zooparasitological Institute)




Fig. 9 *Otostrongylus circumlitus*. Spicule. Original. Magnification 170x
(Photographic Archives, Zooparasitological Institute)

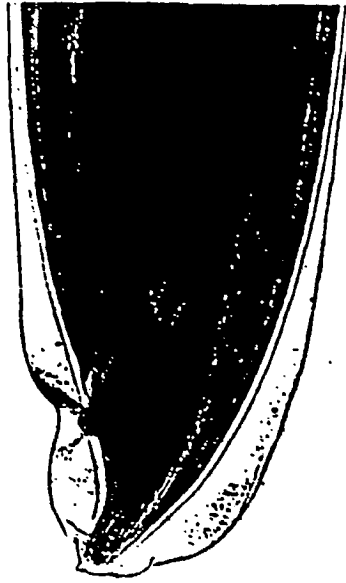


Fig. 10 *Otostrongylus circumlitos*. Posterior end of a female. Original. Magnification 85x (Photographic Archives, Zooparasitological Institute)




Fig. 11 *Otostromgylus circumlitus*. First-stage larva. Original.
Magnification 270x (Photographic Archives, Zooparasitological
Institute)